

# TALAR DOME WEDGE ALLOGRAFT

BIOLOGICS

## RETROSPECTIVE REVIEW: LATERAL COLUMN LENGTHENING AND COTTON OSTEOTOMY IN FLATFOOT RECONSTRUCTION

By Gregory S. Anderson, DPM, FACFAS and Zachary W. Anderson, DPM, FACFAS

### PATIENT HISTORY

The adult acquired flatfoot deformity is correctable by numerous procedures. Of those, the lateral column calcaneal osteotomy (Evans) and Cotton osteotomy have become major mainstays in flatfoot reconstruction.<sup>1,3,6,7,12</sup> Both of these osteotomies require the use of an interposing bone wedge. Traditionally a tricortical autograft from the iliac crest is used.<sup>4,11</sup> Autologous bone graft has the benefits of osteoinductivity, osteoconductivity, and appropriate biomechanical resistance.<sup>9</sup> However, the use of autologous bone graft does not come without its share of drawbacks. Donor site morbidity, as well as increased operating room time, are among those factors, which may dissuade the surgeon from its use.<sup>9</sup> The utilization of allograft bone wedges has demonstrated to be an acceptable alternative to autologous bone graft.<sup>9</sup>

Originally, Evans described a bone graft harvest from the ipsilateral tibia.<sup>4</sup> Later, Mosca published an autograft harvest from the iliac crest.<sup>11</sup> In recent years, Kim et al. reported on the significant incidence of morbidity of iliac bone graft harvesting. These included: a 16.5% pain at harvest site rate, 29.1% numbness, 3.9% scarring, 15.1% difficulty walking, and 5.9% irritation from clothing. Shifting toward an allograft approach can avoid these types of complications entirely.<sup>8</sup>

An allogenic bone graft has the benefits of being widely available and bypasses the need for an additional operative procedure. Furthermore, graft incorporation rates are similar to those of autograft. A tricortical iliac crest allograft for Evans osteotomy, in particular, has been used and shown to be highly effective.<sup>9</sup> Given that iliac crest allograft is likely to be successful, it begs the question if other types of bone allograft would have similar incorporation rates.

The talar dome bone allograft (**FIGURE 1**) has the benefit of being strong structurally, allowing for excellent osteoconductivity. One issue the principal author has found in general use of a tricortical iliac allograft as a wedge is the ease with which the cancellous

portion can get crushed (**FIGURE 2**). Loss of mechanical integrity can potentially lead to dorsal dislocation of the wedge, fracture, or loss of correction. The talus bone is stronger by nature and can hold up to the forces placed upon it, with opposing walls of bone.

The talar dome bone allograft has been used in osteochondral defect grafting using osteochondral talus bone. To our knowledge, however, we are unaware of any literature reporting the use of talar bone graft in the use of osteotomies for flatfoot reconstruction. Here, the principal author aims to report on the use of talar dome allograft in Evans and Cotton osteotomies in the correction of the adult acquired flatfoot.



FIGURE 1

Talar Dome unicortical bone blocks: Large (left), Medium (right)




FIGURE 2

Cancellous matrix comparison: Talar Dome (left), tricortical iliac allograft (right)

## PATIENTS AND METHODS

The present study was a retrospective case series review of patients undergoing pes planovalgus reconstruction, including either an Evans and/or a Cotton osteotomy from December 2017 to November 2018. The principal author performed all procedures. The inclusion criteria were either an Evans or Cotton osteotomy, a diagnosis of pes planovalgus or posterior tibial tendon dysfunction, and a minimum age of 18 years. Exclusion criteria included end-stage posterior tibial tendon dysfunction requiring hindfoot fusion and smoking.

The patient demographics including age, gender, tobacco use, and a generalized health history, were recorded. The procedure-specific data include fixation with either a bone staple or two-hole locking plate. The osteotomies were undertaken with a talar dome wedge graft. Post-operative and radiographic data included time-to-osseous fusion with serial radiographs.

Additional procedures for the pes planovalgus reconstruction included an endoscopic gastrocnemius recession, medial displacement calcaneal osteotomy, lapidus procedure, bone marrow aspirate, flexor digitorum tendon (FDL) transfer with posterior tibial tendon advancement and one instance of medial column fusion with beaming.

## SURGICAL TECHNIQUE

All procedures were performed under general anesthesia. Patients were in a supine position with an ipsilateral hip bump (which was removed during medial procedures, including tendon transfer). A sufficiently-padded thigh tourniquet held at 300mmHg was used for initial hemostasis. In all cases, a gastrocnemius lengthening procedure was performed first with an endoscope. This was followed by a medial displacement calcaneal osteotomy. Those patients who needed an Evans osteotomy had that performed subsequently.

The Evans lateral calcaneal lengthening osteotomy was performed at 1.2 to 1.5cm proximal to the calcaneal cuboid joint. If the bone cut is performed too close to the calcaneocuboid joint, there is a risk for distal fragment instability.<sup>1</sup> The osteotomy was made with a sagittal saw and levered open with a 10mm osteotome. The medial cortex of the calcaneus was left intact to prevent dorsal dislocation of the distal calcaneal fragment. After a sufficient space for either a 6 or 8mm wedge was obtained, a trapezoidal wedge of talar dome graft was inserted into the osteotomy site (**FIGURE 3**). The talar dome grafts came en bloc and needed to be cut into a wedge shape by the principal author (**FIGURES 4 & 5**). Osteotomies were either fixated with staples (**FIGURE 6**) or a two-hole locking plate.

In instances where a Cotton osteotomy was needed, this procedure followed the lateral calcaneal lengthening. Bone cuts were made dorso-medially at the central portion of the medial cuneiform. In similar fashion to the Evans osteotomy, the bone cut

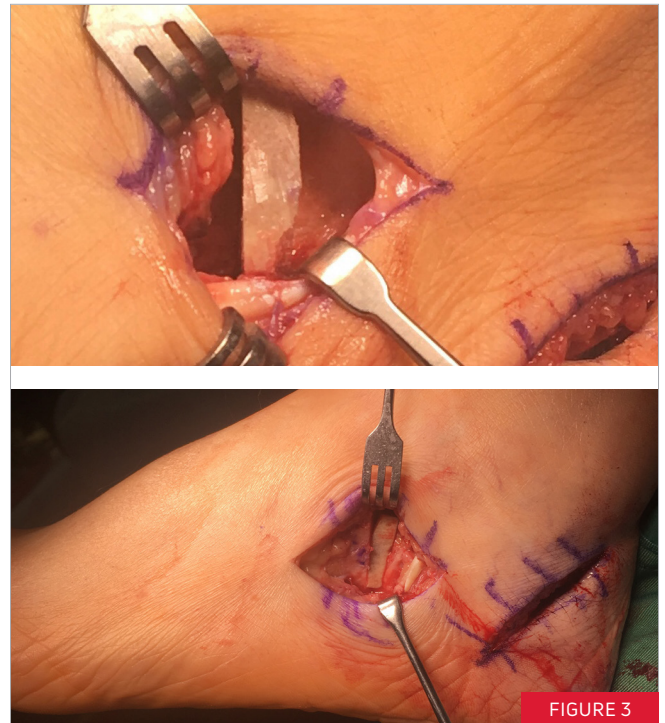


FIGURE 3

*6mm wedge placed for an Evans osteotomy*

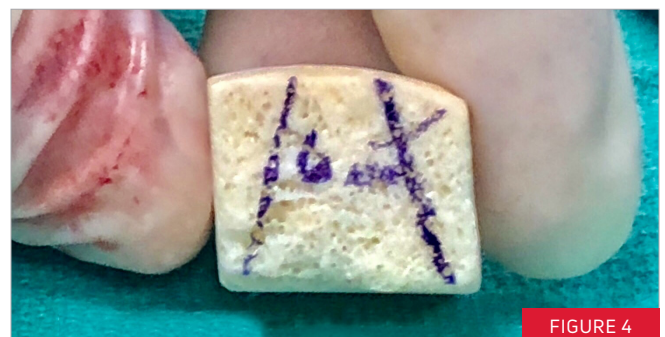

FIGURE 4

*Talar Dome graft marked to fashion two 6mm grafts*

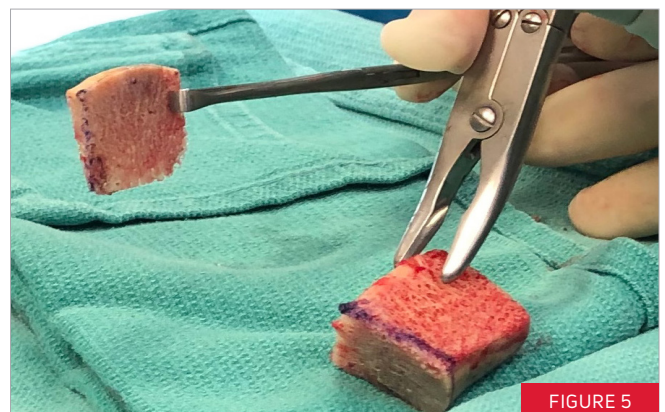

FIGURE 5

*Talar Dome used to fashion wedge-shaped grafts for Evans and Cotton procedures*

did not pass through the plantar cortex, and the osteotomy was levered open with an osteotome (**FIGURE 7**). Residual graft from the talar dome allograft was fashioned into a 6-8mm trapezoidal wedge (**FIGURE 5**) and inserted into the bone cut. Fixation was achieved with either bone staples (**FIGURE 8**) or a two-hole locking plate. Additional procedures such as FDL tendon transfer, posterior tibial tendon advancement and repair, and hallux valgus and hammertoe correction were then performed.

Using mini C-arm fluoroscopy a final dorsoplantar (DP) and lateral weight-bearing images were taken (**FIGURES 9-11**). Patients were placed in a modified hand dressing and Jones compression posterior splint. Follow-up serial radiographs were taken at ten days, four weeks, eight weeks, and twelve weeks. Radiographic union of the graft was determined by the principal author in all cases. Graft pain was also recorded at each follow-up visit.

## RESULTS

A total of nine patients met the inclusion criteria. The patient demographics are listed in **TABLE 1**. Eight patients had an Evans osteotomy performed. Likewise, eight patients received a Cotton osteotomy. In total, there were 16 osteotomies performed in the study, 15 of which, achieved osseous union (93.8%). Six patients received both Evans and Cotton osteotomies. The mean time to osseous union was approximately ten weeks (see **TABLE 1**). There was one patient who sustained a fall two weeks postoperatively and dislocated the plate and wedge graft. There was an immediate loss of surgical correction in that patient and they went on to a non-union. This patient was scheduled for a complete hindfoot valgus reconstruction, including a medial column fusion. During that surgery the patient received an Evans calcaneal osteotomy, as an adjunctive procedure, and went on to heal the osteotomy site with bony fusion. There were two instances of painful hardware. One of those patients has developed chronic pain in the foot (not isolated to the osteotomy sites) and is having continued treatment for the chronic pain.

## DISCUSSION

The original intent of this study was to review the use of talar dome wedge allograft in Evans and Cotton procedures to correct adult acquired flatfoot deformities. The use of talar dome allograft is an alternative to the tricortical iliac crest allograft, which has been shown to be an acceptable alternative to using the patient's autograft. To the authors' knowledge, there has not been a study of the talar dome allograft in flatfoot reconstructive surgery. The lateral column lengthening procedure was first described by Evans and was described as an osteotomy of the calcaneus using an interpositional bone graft. The Evans osteotomy is widely-held as a substantive procedure in correcting a pes planovalgus foot. Evans held that the lateral column of the foot held a significant influence of the shape and function of the foot.<sup>4</sup> We agree with this idea and feel that the use of talar dome allograft adds to the

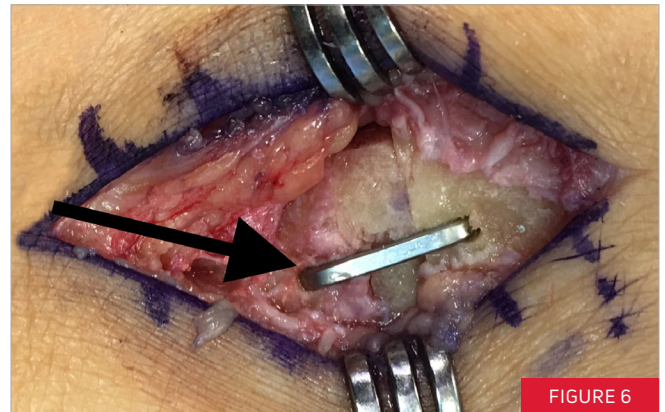


FIGURE 6

*Evans osteotomy fixated by a Sniper Staple*

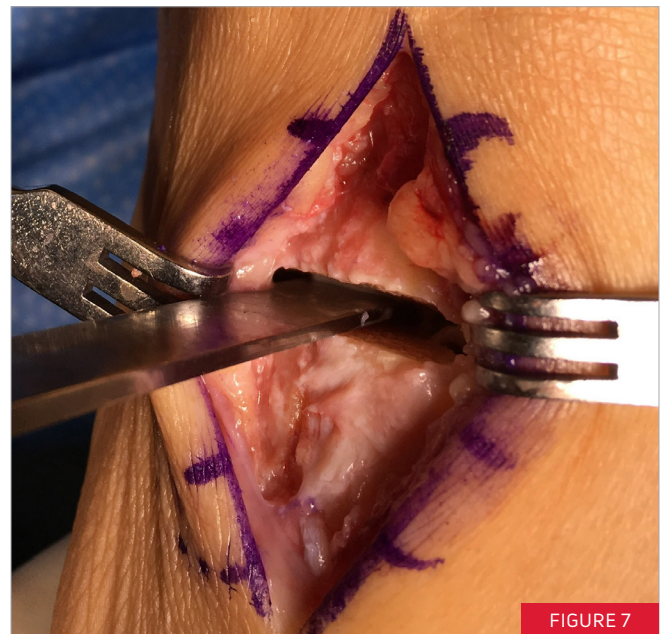

FIGURE 7

*Cotton osteotomy opened to place graft*

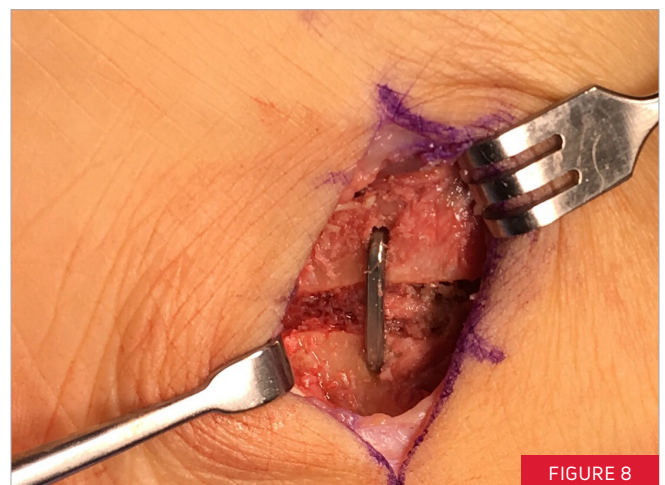

FIGURE 8

*Cotton osteotomy fixated by a Sniper Staple*

**TABLE 1**

PATIENT #	SEX	AGE (YEARS)	DATE OF SURGERY	EVANS	COTTON	UNION (WEEKS)	COMPLICATIONS
1	F	51	12/15/17		✓	8	
2	F	68	01/05/18	✓		13	
3	F	72	2/23/18	✓	✓	10	
4	F	54	5/16/18	✓	✓	16	PAINFUL HARDWARE
5	F	74	7/13/18	✓	✓	9	PAINFUL HARDWARE
6	M	64	10/19/18	✓	✓	8	
7	F	61	07/06/18		✓		PATIENT FELL 2 <sup>ND</sup> WEEK, FRACTURED HARDWARE
7*	F	61	11/30/18	✓		6	
8	F	66	11/28/18	✓	✓	11	
9	M	48	11/16/18	✓	✓	8	
AVG. 62				8	8	MEAN 9.89	

\*Patient #7 sustained a fall in the second week of her post-operative course. That patient had a revision surgery wherein an Evans osteotomy was performed. That patient went on to radiographic boney incorporation at 6 weeks, as indicated in the above table.

structural integrity of the osteotomy and still allows for good boney ingrowth.

Similarly, a Cotton osteotomy has become a significant adjunct to pes planovalgus reconstruction and requires an interposition bone graft.<sup>2</sup> A plantar flexion opening wedge medial cuneiform osteotomy was first described by Cotton (1936) in order to restore a plantigrade foot and has since been widely employed to treat supination in a flatfoot reconstruction.<sup>2,10</sup> Later studies of the Cotton osteotomy have shown a high rate of union.<sup>7</sup> The results of this retrospective review similarly show a high rate of union with the use of talar dome allograft.

In the present study, the aim was to present the outcomes of talar dome allograft use in both Evans and Cotton osteotomies for pes planovalgus reconstruction. To our knowledge, there has not been a study produced where talar dome allograft has been used as a wedge graft in flatfoot reconstruction. Our findings show that the use of talar dome allograft for the Evans and Cotton osteotomies can be an acceptable approach to the Evans and Cotton osteotomies. The talar dome allograft can be considered an alternative to iliac tricortical allograft and may have significant clinical applications. With talus bone being a good allograft option, it adds to the number of viable grafting options. Furthermore, the inherent structure and strength of talus bone may prove to be a superior property to iliac tricortical graft.

Whereas the talar dome allograft has not been examined previously in flatfoot reconstruction, its implementation has been studied in large osteochondral lesion surgery. Raikin et al. evaluated osteochondral talar en bloc allograft for the repair of large cystic lesions in the talus. That study showed improvements in patients' pain, activity levels, and walking distances. Patients saw an overall AOFAS ankle-hindfoot scores of 45 points.<sup>15</sup>

In a different study of nine isolated osteochondral allograft implantations on the talar side for the treatment of Berndt and Harty grade-IV lesions, Gross et al. reported that six grafts survived an average of eleven years.<sup>5</sup>

These are remarkable results in the two osteochondral talus grafting studies given the fact of the large size of the grafts, and involvement of the ankle joint. There is no involvement of a joint with Evans or Cotton osteotomies, nor do they require as large of talus graft material than in osteochondral surgery. The value of remarking on these studies is the fact that the talar graft was successfully used, and that the graft material could withstand the high force and motion found in the ankle joint. This encourages us that talar dome allograft can be successful in basic geometry applications such as Evans and Cotton osteotomies.

This study has a few limitations, including its retrospective nature. The sample size is not exceptionally high. Not every supple flatfoot is the same and requires a different combination of procedures.

Therefore, having a study comparing different flatfoot reconstructions does not lend itself well to uniform comparison. Lastly, the follow up is limited to one year in some cases.

In conclusion, we believe that talar dome allograft for wedge osteotomies in pes planovalgus reconstruction can be a safe and viable option. The results of this investigation could be useful for future research aimed at designing randomized controlled trials and prospective cohort studies.

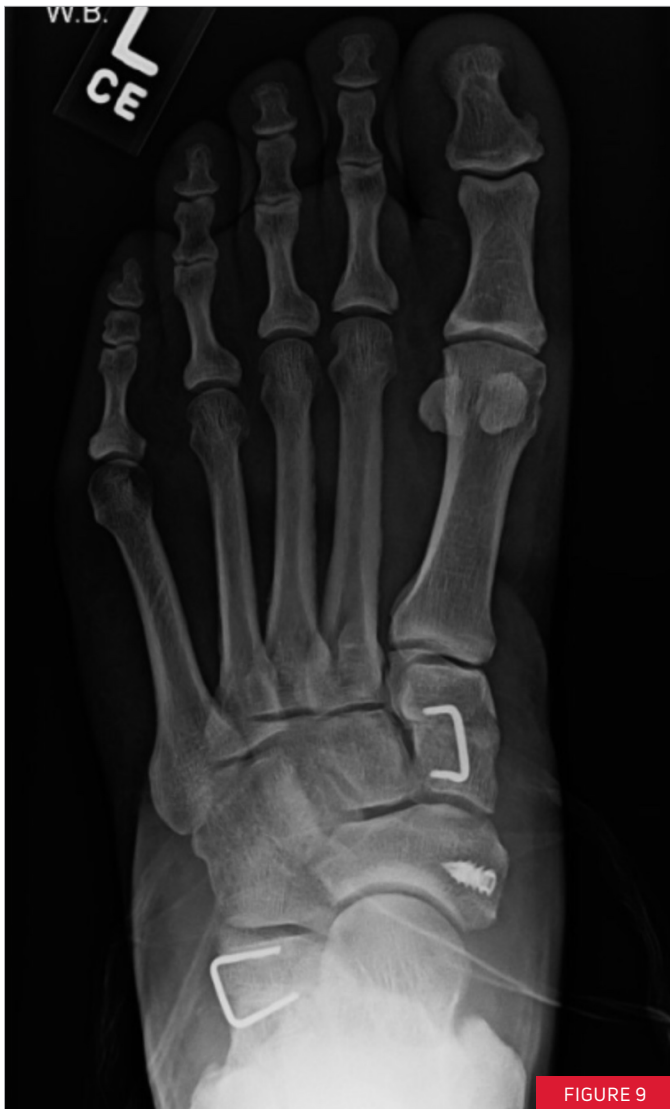

FIGURE 9

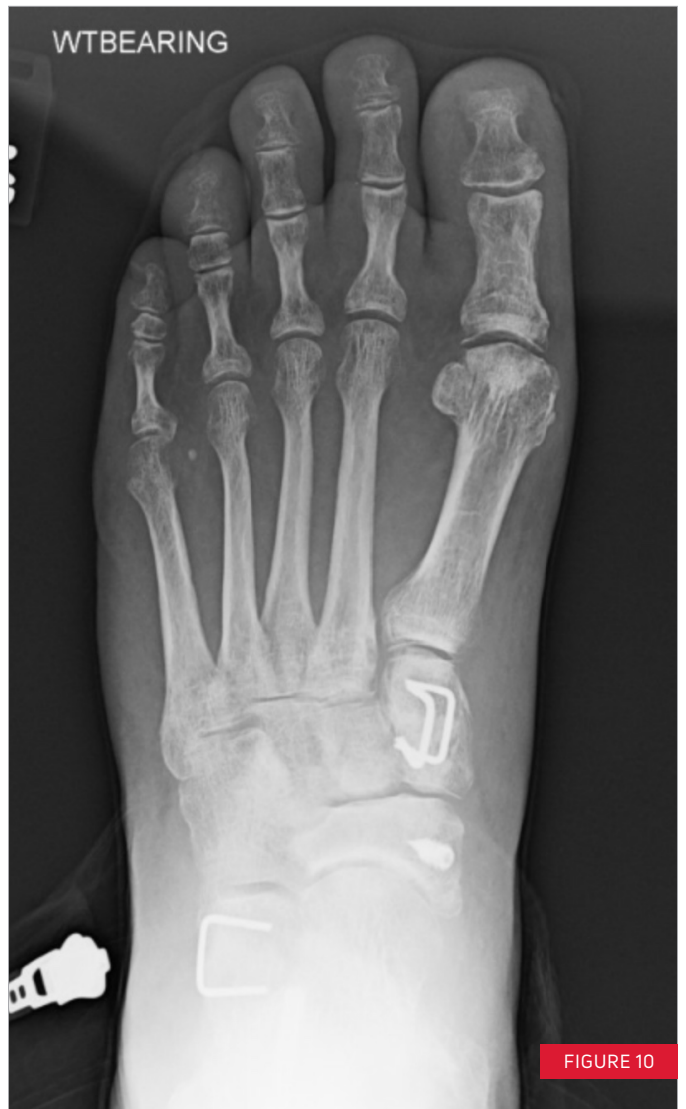

FIGURE 10

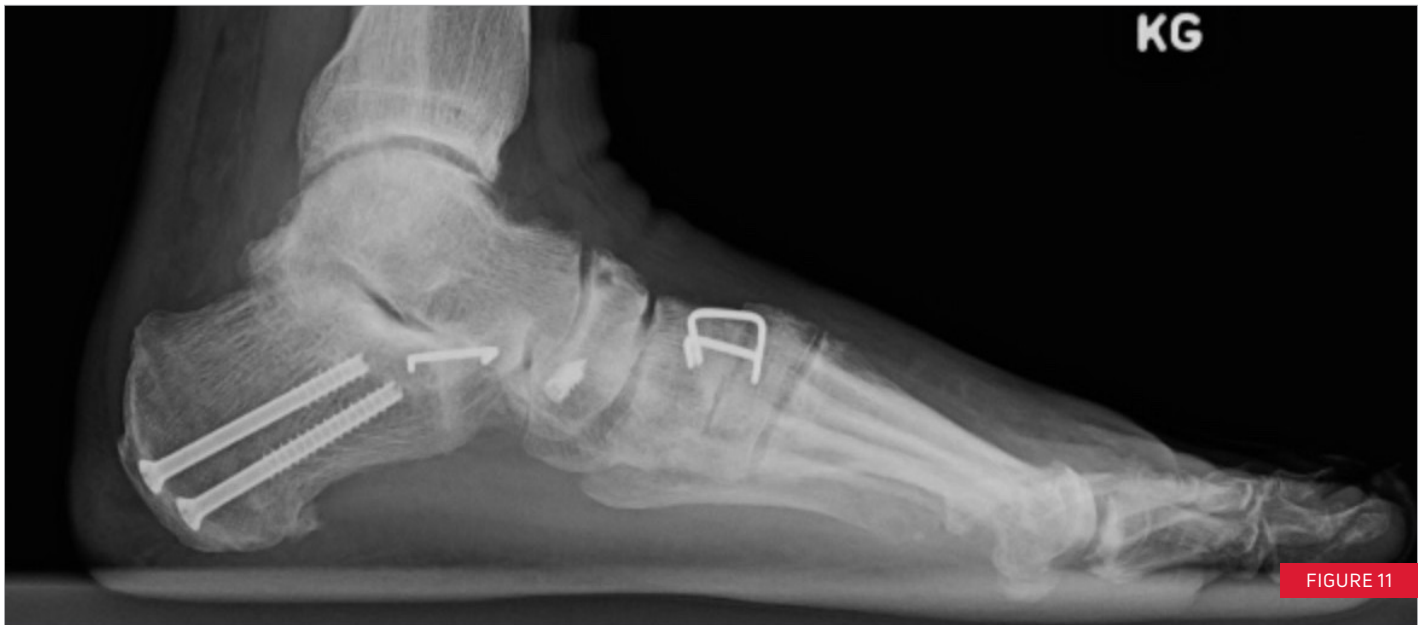

FIGURE 11

## REFERENCES

1. Butterworth, M. (2011). Maximizing the effectiveness of the Evans calcaneal osteotomy. *Podiatry Today*, 26(9), 20-26.
2. Cotton, F. J. (1936). Foot statics and surgery. *The New England Journal of Medicine*, 214(8), 353-362.
3. Dollard, M. D., Marcinko, D. E., Lazerson, A., & Elleby, D. H. (1984). The Evans calcaneal osteotomy for correction of flexible flatfoot syndrome. *The Journal of Foot Surgery* 23(4), 291-301.
4. Evans, D. (1975). Calcaneo-valgus deformity. *The Journal of Bone & Joint Surgery. British volume*, 57(3), 270-278.
5. Gross, A. E., Agnidis, Z., & Hutchison, C. R. (2001). Osteochondral defects of the talus treated with fresh osteochondral allograft transplantation. *Foot & Ankle International*, 22(5), 385-391.
6. Guha, A. R., & Perera, A. M. (2012). Calcaneal osteotomy in the treatment of adult acquired flatfoot deformity. *Foot and Ankle Clinics* 17(2), 247-258.
7. Hirose, C. B., & Johnson, J. E. (2004). Plantarflexion opening wedge medial cuneiform osteotomy for correction of fixed forefoot varus associated with flatfoot deformity. *Foot & Ankle International*, 25(8), 568-574.
8. Kim, D. H., Rhim, R., Li, L., Martha, J., Swaim, B. H., Banco, R. J., ... & Tromanhauser, S. G. (2009). Prospective study of iliac crest bone graft harvest site pain and morbidity. *The Spine Journal*, 9(11), 886-892.
9. Mahan, K. T., & Hillstrom, H. J. (1998). Bone grafting in foot and ankle surgery. A review of 300 cases. *The Journal of the American Podiatric Medical Association*, 88(3), 109-118.
10. McCormick, J. J., & Johnson, J. E. (2012). Medial column procedures in the correction of adult acquired flatfoot deformity. *Foot and Ankle Clinics*, 17(2), 283-298.
11. Mosca, V. S. (1995). Calcaneal lengthening for valgus deformity of the hindfoot. Results in children who had severe, symptomatic flatfoot and skewfoot. *The Journal of Bone & Joint Surgery* 77(4), 500-512.
12. Moseir-LaClair, S., Pomeroy, G., & Manoli, A. (2001). Intermediate follow-up on the double osteotomy and tendon transfer procedure for stage II posterior tibial tendon insufficiency. *Foot & Ankle International* 22(4), 283-291.
13. Raikin, S. M. (2009). Fresh osteochondral allografts for large-volume cystic osteochondral defects of the talus. *The Journal of Bone & Joint Surgery* 91(12), 2818-2826.



T 800.495.2919 F 877.778.3864

Trilliant Surgical, LLC  
727 N Shepherd Drive | Suite 100 | Houston, TX 77007 | U.S.A.  
enovis.com/foot-and-ankle

Copyright © 2021 by DJO, LLC  
900-30-009 Rev B

NOTE: The views and opinions expressed in this white paper are those of the author. Individual results may vary. Neither Trilliant Surgical, LLC nor any of the Enovis companies dispense medical advice. The contents of this document do not constitute medical, legal, or any other type of professional advice. Rather, please consult your healthcare professional for information on the courses of treatment, if any, which may be appropriate for you.